
Prescription-Based Precision Full Arch Indirect Bonding

John T. Kalange

A highly evolved and extremely accurate method for precision bracket placement is described in which vertical and horizontal reference lines are placed on working models to create a visual template for bracket placement. These lines are based upon the concept of coupling defined treatment objectives with the functional requirements of level marginal ridges and canine and incisor guidance. This prescribed method is unique for each individual, and inherently accounts for the eight criteria established by the American Board of Orthodontics for case acceptance. Furthermore, this system ensures the ultimate objective of idealized anterior gingival margin contour and overall excellence in facial esthetics. (Semin Orthod 2007;13: 19-42.) © 2007 Elsevier Inc. All rights reserved.

In 1998, the American Board of Orthodontics (ABO) submitted to the profession an objective grading system to be used in the evaluation and scoring of cases submitted for board certification. As stated in the original publication, the Board intended to create this system, “in an effort to enhance the reliability of the examiners and provide the candidates with a tool to assess the adequacy of their finished orthodontic results” and to establish an objective grading system “to evaluate the final dental casts and panoramic radiographs.”¹ The ABO Objective Grading System for scoring dental casts and panoramic radiographs consists of eight criteria: alignment, marginal ridges, buccolingual inclination, occlusal relationships, occlusal contacts, overjet, interproximal contacts, and root angulation. Fortuitously, the author published an article in the *Journal of Clinical Orthodontics* in September 1999, describing a method for indirect bracket placement that inherently, either directly or indirectly, accounted for these eight criteria in the setup process.² Although the basic tenets of this original concept remain, it has by

way of continued evaluation, trial and practice, evolved into the current state of precision.

Existing Bracket Placement Guidelines

Before presenting the particulars of the proposed technique, it is considered appropriate to offer a preface by discussing previously mentioned methods for bracket placement.

Andrews revolutionized orthodontics, and forever changed the specialty of orthodontics, by originating the concept of the Straightwire Appliance® and the “Six Keys To Normal Occlusion.”³ Concerning bracket placement, Andrews specifically designed brackets for each tooth, such that when seated correctly, the bracket base fit on a specific portion of the tooth referred to as the FA point. This FA point represented the midpoint of the tooth that separates the gingival half of the clinical crown from the occlusal half. In other words, this represents the center of the clinical crown on the facial axis. When all of the FA points are lined up from a horizontal perspective, this creates a plane referred to as “Andrews Plane.” Andrews argued if the FA points were ideally positioned on this plane, the teeth would be optimally positioned.

The concept of using the center of the clinical crown for a reference point for bracket placement has sound theoretical foundations; however, in the clinical situation, this point of

*From the private practice of Dr. John T. Kalange, Boise, ID.
Address correspondence to John T. Kalange, DDS, MS, 136 E. Mallard Dr., Boise, ID 83706. Phone: 208-342-0212; E-mail: john911sc@aol.com*

© 2007 Elsevier Inc. All rights reserved.
1073-8746/07/1301-0\$30.00/0
doi:10.1053/j.sodo.2006.11.005

view has many deficiencies. In fact, it can be argued that using the center of the clinical crown for bracket placement does not optimize the occlusion in most of the patients whom we treat. The reasons for this statement are complex and varied, and would require a separate forum for clarification. However, a few examples of why this statement is valid can be summarized here.

If the center of the clinical crown is used as a point for positioning brackets in a deep overbite situation in which there are large anterior teeth and small posterior teeth, this would tend to deepen the bite and thereby complicate the treatment. Similarly, using the center of the clinical crown for bracket positioning will complicate an open-bite patient who has large posterior teeth and small anterior teeth. If there is a large upper central incisor and a small upper lateral incisor, placing brackets in the center of the clinical crowns would create an unesthetic gingival margin contour, because the lateral incisor will be overerupted compared with the central

incisor. In the majority of the patients orthodontists treat, the second bicuspid tooth is smaller than the first bicuspid tooth. Using the center of the clinical crown on these bicuspid teeth would serve to intrude the second bicuspid, thereby creating a marginal ridge discrepancy and a posterior open bite. In this situation the bracket on the second bicuspid tooth should optimally be located more gingival relative to the first bicuspid tooth. Experience has shown that placing brackets in the center of the clinical crown on the lower teeth generally places them too far to the occlusal and the incisal surfaces, and the latter creates interferences that result in notching of the upper teeth and numerous loose or displaced appliances. Orthodontics has seen a trend toward the treatment of an increasing number of adult patients. These patients quite frequently demand customization of bracket placement for restorative and periodontal reasons. Obviously, using the center of the clinical crown in these situations would be less than optimal.

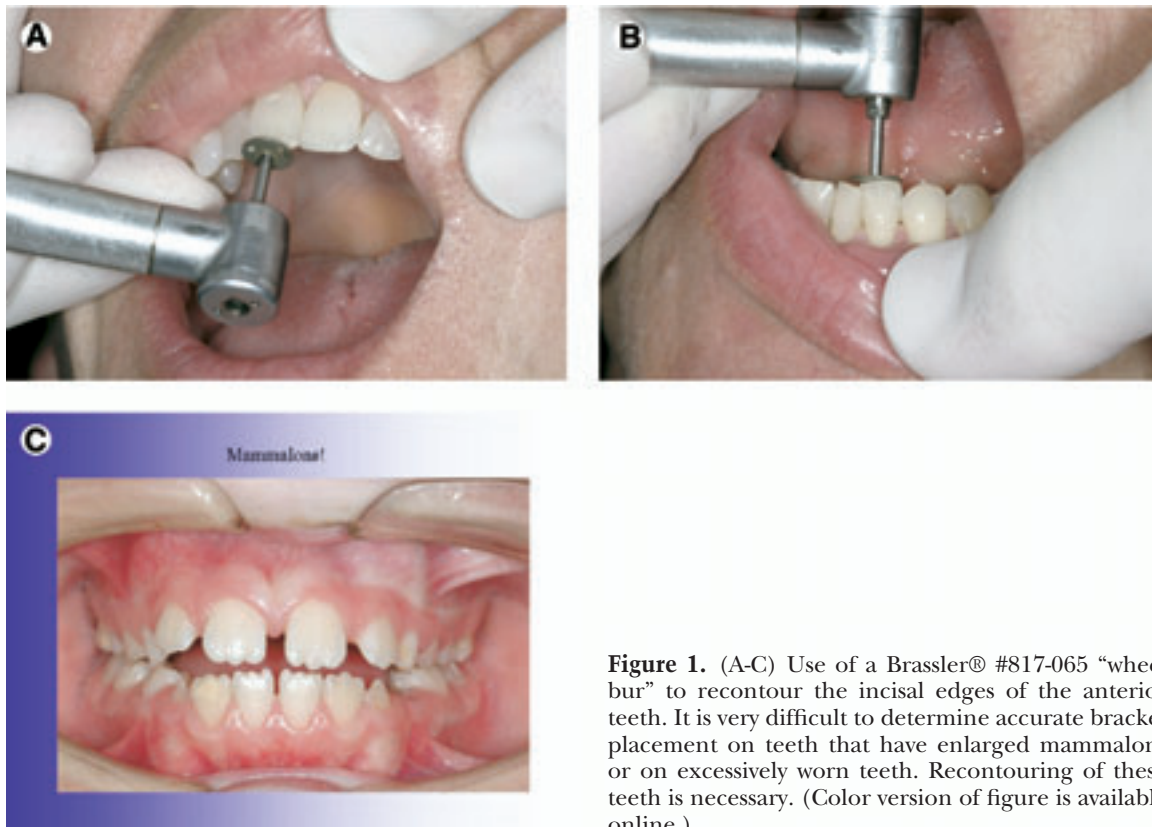


Figure 1. (A-C) Use of a Brassler® #817-065 “wheel bur” to recontour the incisal edges of the anterior teeth. It is very difficult to determine accurate bracket placement on teeth that have enlarged mammalons or on excessively worn teeth. Recontouring of these teeth is necessary. (Color version of figure is available online.)

Table 1. Armamentarium for Prescription Based Precision Bonding

Laboratory
Dental Stone
Vacuum Mixer
Black lead pencil .03mm
Red lead pencil .05mm
Bow divider
Millimetric ruler
Magnifying glasses
Separating agent
Brackets and custom base resin
Invecta® TN3 bracket seating instrument
Millimetric Probe (Hu-Friedy® PCPUNC 15)
Explorer (Shein® exp 23)
Triad 2000® light-curing unit
Unitek® cement guards #406-041
Exaflex® VHV Putty
Mixing bowl and warm water
Clean tooth brush
Danville Engineering® Microetcher
50-micron aluminum oxide
Clinical
High-speed handpiece
Brassler® #817-065
Slow-speed handpiece and prophyl cup
Pumice
Alginate and Alginate II®
Dappen dish
Cotton pliers
Sponge pellets
Nola Dry Field System®
High and slow speed evacuation
Air/water syringe
37% phosphoric acid etchant
Transfer trays with brackets and custom bases
Bonding resin
Second hand timer

In a landmark publication, Roth discussed orthodontic treatment planned and delivered from a functional occlusal perspective.⁴ Appliance placement in this philosophy is predicated on placing brackets on the point of maximum convexity of the bicuspid, with the tip of the cuspid 1 mm longer than the tip of the adjacent bicuspid and 1 mm longer than the adjacent lateral incisor. The maxillary central incisors are bracketed equal in height to the maxillary lateral incisor, with the assumption the “centrals will elongate to ½ mm to 1 mm longer than the laterals after settling.”⁵ The experience of this author is that allowing for “settling” to finish a case is unpredictable and unreliable, and therefore this author prefers to place the teeth in their final position at the end of treatment.

A portion of the MBT® philosophy (Unitek, Monrovia, CA) includes a “Recommended Bracket Positioning Chart.”⁶ This chart is used as

a road map for placement of brackets based on measuring the length of the central incisor. After the length of the central incisor has been established, it is referenced to the bracket-positioning chart for measurements for bracket placement for the remainder of the arch. Final bracket placement is accomplished with the aid

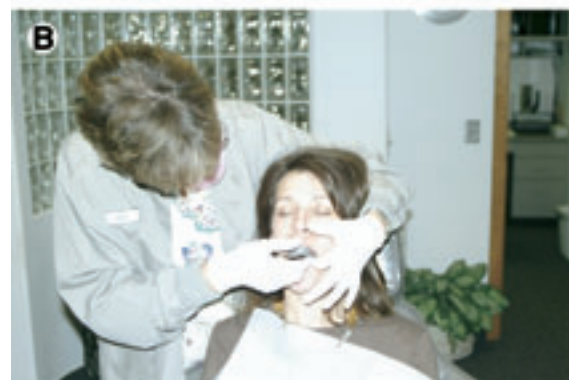

Figure 2. (A and B) Assistant obtaining accurate mechanically mixed alginate impressions. (Color version of figure is available online.)

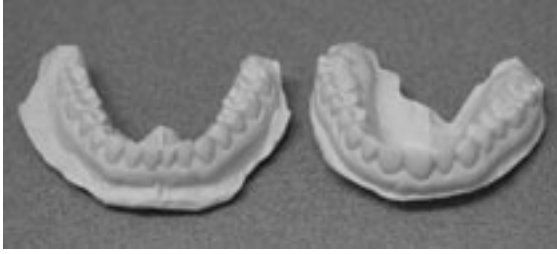

Figure 3. Working models.

of specialized bracket-positioning gauges. Although this approach has proved to be accurate and reliable, there are inherent limitations in using these charts. These charts are predicated on a dentition in which all of the teeth are ideally proportioned, which rarely occurs. As an example, oversized central incisors might lead to brackets that are overseated on a remaining arch that has generally small teeth. A small central incisor in a patient with overall large teeth might result in those brackets being underseated. Although the use of these charts will result in good overall positioning of the teeth, they do not take into account the necessity for level marginal ridges and require modification in deep-bite, open-bite, and extraction cases.

Orthodontic appliances are currently being manufactured to very small tolerances using sophisticated computer-aided design and robotic machines. To take full advantage of the precision built into these appliances, an equally precise method for attaching them to the dentition is required. A technique will be proposed, in which a prescription for precision bracket placement will be used to effect idealized, customized, and optimal bracket placement for each individual patient.

Technique and Armamentarium

The first step in this process involves obtaining accurate alginate impressions of the dentition. However, it has been found that it is critical to have incisal edges that are very near their final contour before taking impressions and beginning treatment. The reason for this is that the reference for bracket placement in the anterior region in this technique is the incisal edge. Also, it is very difficult to determine exactly how much recontouring is necessary, and what the shape of the teeth should be if a bracket is placed on the

tooth first. This author concluded, after several years of evaluation, that if recontouring of the teeth at some point in time would become necessary anyway, it logically made sense to do it before the impressions were taken so that this approach would enhance the overall accuracy of the process. Therefore, it is recommended that recontouring of the incisal edges using a high-speed hand piece and a Brassler® #817-065 bur be performed before impression taking (Fig 1A and B, Table 1). A series of articles by Kokich serves as an excellent reference for tooth recontouring.⁷⁻⁹ It might also be necessary to place “provisional” or temporary restorations or to restore anterior teeth that are broken down before taking impressions.

If necessary, clean the teeth with a prophyl cup and pumice, and then take accurate alginate impressions using mechanically mixed alginate (Fig 2A and B). Pour the impressions with vacuum-mixed stone. Rough trim the casts enough to allow for good visualization of the teeth, and then allow them to dry thoroughly (Fig 3).

The next step involves placing vertical and horizontal reference lines on the models. It is very important to make these lines as thin as possible and yet visible. Using an ordinary lead pencil creates lines that are much too thick and diminishes the accuracy of the setup (Fig 4). To illustrate this point, the difference between a 0.07-mm black lead line and a 0.03-mm black lead in a mechanical pencil when drawn on paper is almost 1 mm. This implies that there is a potential of almost 1 mm in variance in bracket

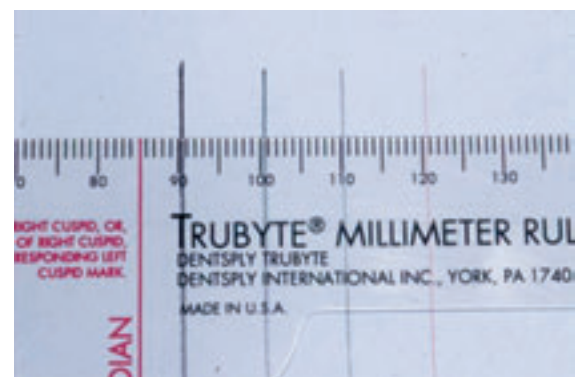


Figure 4. Lines drawn with various mechanical pencils. Note that a thicker line is almost 1 mm in thickness, which diminishes the accuracy of the setup. (Color version of figure is available online.)

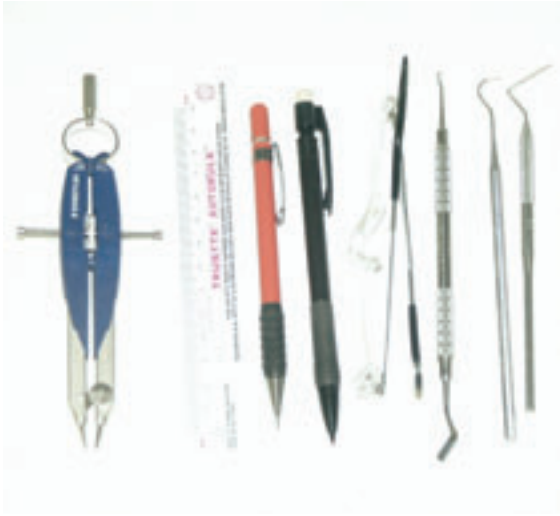

Figure 5. Items used for the setup. (Color version of figure is available online.)

positioning when using a 0.07-mm pencil versus a 0.03-mm pencil. This author uses a 0.03 mm black lead pencil, and a 0.05 mm red pencil (Fig 5). The red pencil is 0.05 mm versus 0.03 mm simply because this is the smallest diameter of red lead that has been found available.

Using the 0.03-mm black lead pencil, draw vertical lines on the upper and lower casts of the teeth from the second bicuspid forward, beginning on the crowns and continuing down the model onto the roots (Fig 6A-C). These lines indicate the long axes of the teeth.

Next, using the red lead pencil, draw horizontal lines on both models on the molars and bicuspids connecting the mesial and distal marginal ridges (Fig 7A and B). Using a bow divider, measure 2 mm between the tips of the divider, (Fig 8), and then transfer this measurement to the working models by making a faint scratch mark on the vertical pencil lines (Fig 9). Use this mark to place a second line parallel to the marginal ridge line. On the second molar, decrease this measurement by $\frac{1}{2}$ mm (Fig 10A and B). This is the slot line, and when brackets are placed here and a level arch wire is engaged, it will align the marginal ridges of the posterior teeth, and place the cusp tips on a level plane. The 2-mm slot line measurement is somewhat arbitrary and can be increased or decreased based on the size of the teeth. For instance, a 2.5-mm measurement might be more appropri-

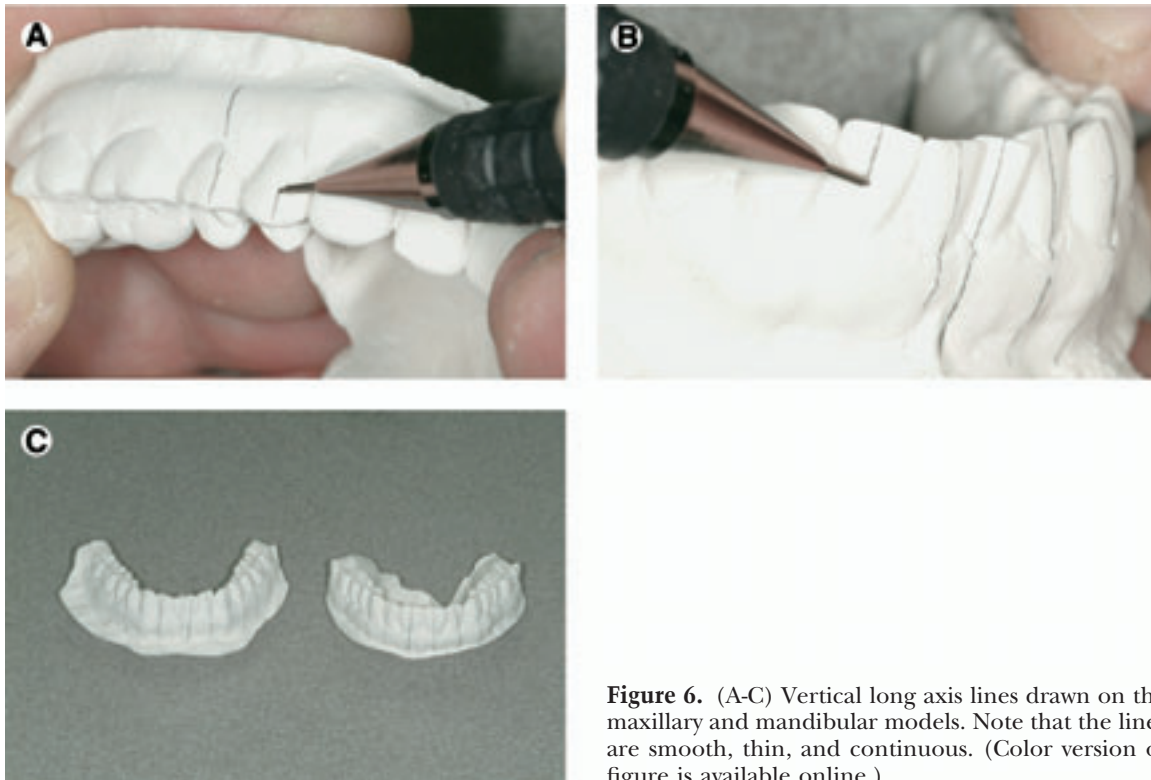


Figure 6. (A-C) Vertical long axis lines drawn on the maxillary and mandibular models. Note that the lines are smooth, thin, and continuous. (Color version of figure is available online.)

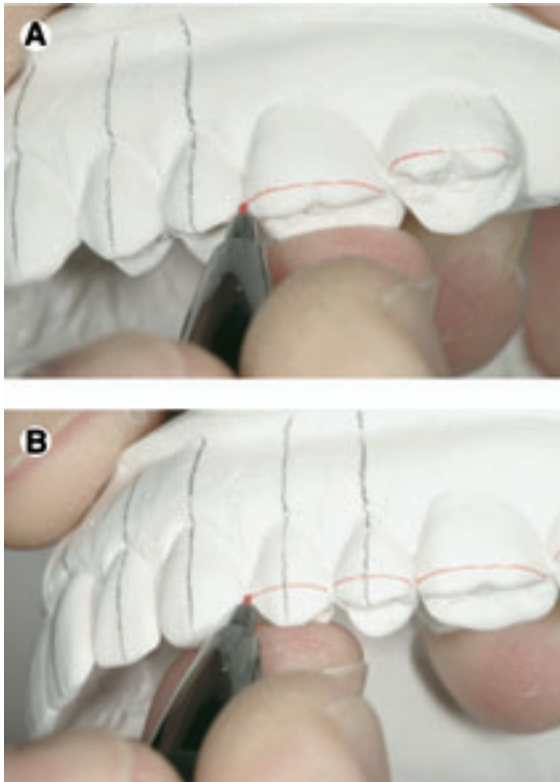


Figure 7. (A and B) Marginal ridge lines drawn on the posterior teeth. (Color version of figure is available online.)

ate for larger teeth and will place the brackets a bit farther out of occlusion.

At this point, there are upper and lower working models with three reference lines on the posterior teeth: the vertical long axis line, the horizontal marginal ridge line, and the horizontal slot line. As a means of connecting the func-




Figure 8. Bow divider set to 2 mm. (Color version of figure is available online.)



Figure 9. Transfer the 2-mm measurement to the bicuspids and first molar. (Color version of figure is available online.)

tional aspects of these lines with the anterior teeth, begin by measuring the distance from the cusp tip on the first bicuspid to the slot line (Fig 11). In this case this measurement happens to be 4.5 mm (Fig 12). This measurement is transferred to the central incisors (Fig 13). The

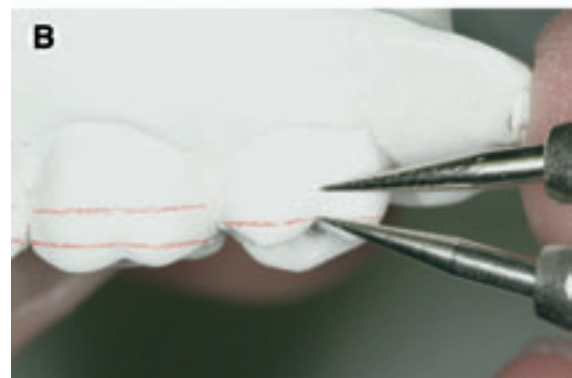

Figure 10. (A and B) Bow divider set to 1.5 mm, and this measurement transferred to the second molar. (Color version of figure is available online.)




Figure 11. Measure the distance from the slot line to the cusp tip on the first bicuspid. (Color version of figure is available online.)

measurement for the maxillary lateral incisor is decreased by 0.5 mm (Fig 14A and B) and increased by 0.5 mm for the canine (Fig 15A and B). There is now an upper model with faint scratch lines on the vertical long axis line for the anterior teeth that will be used for construction of the anterior slot lines (Fig 16A and B). All of the measurements for anterior teeth can be reduced to open the bite and increased to deepen the bite.

The mandibular arch is done in the same manner, with long axis lines and marginal ridge lines placed, followed by the slot line. The measurement for the distance from the cusp tip on the first bicuspid to the slot line is obtained (Fig 17). In this case, this measurement was just less than 4.0 mm (Fig 18) and is transferred to the mandibular central and lateral incisors (Fig 19A and B). This measurement is increased by 0.5 mm for the mandibular canine (Fig 20)




Figure 12. The measurement is 4.5 mm. (Color version of figure is available online.)

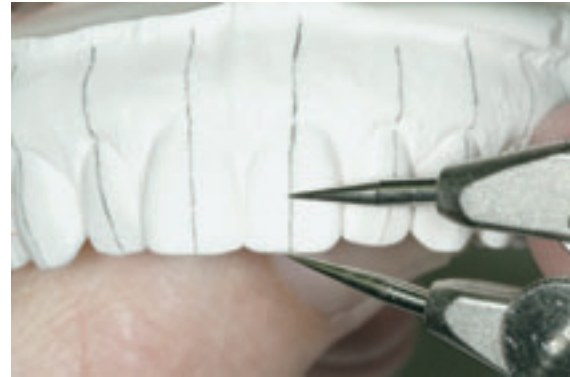

Figure 13. Transfer the 4.5 mm measurement to the central incisor. (Color version of figure is available online.)

and transferred to the working models by means of a light scratch on the vertical long axis line (Fig 21). There is now a mandibular model with faint scratch lines on the vertical long axis line for the anterior teeth that will be used for construction of the anterior slot lines (Fig 22A

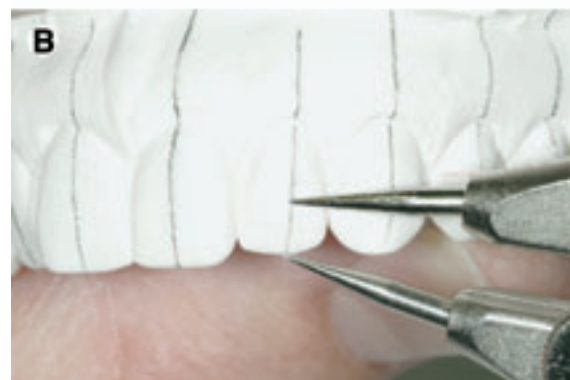


Figure 14. (A and B) Decrease the measurement by 0.5 mm, and transfer to the lateral incisor. (Color version of figure is available online.)

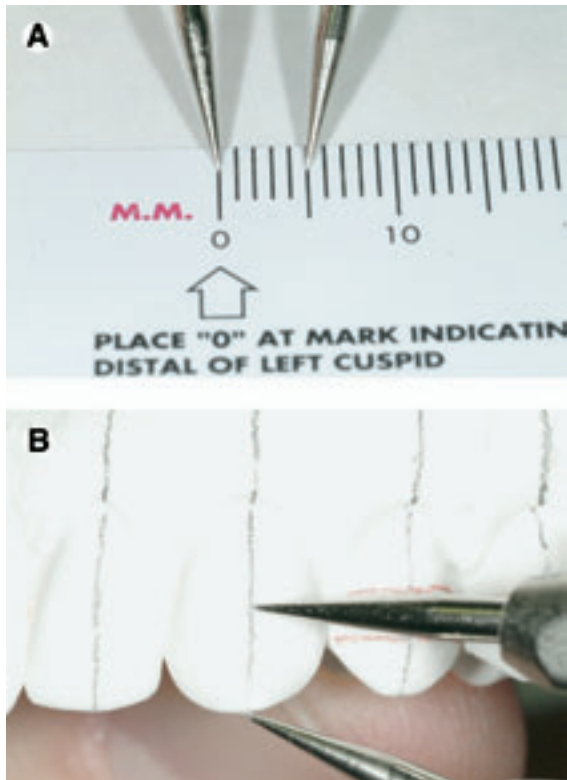


Figure 15. (A and B) Increase the measurement by 0.5 mm, and transfer to the canine. (Color version of figure is available online.)

and B). Again, these measurements can be increased or decreased depending on what treatment objectives have been established.

By placing these lines on the working models, a truly customized prescription for bracket placement has been created (Fig 23). The brackets can be attached to the models and custom bases fabricated in a number of ways.

There are numerous methods in which custom bases can be prepared. A two-part dual cure resin can be mixed and placed on the bracket base (Fig 24). This bracket is then seated onto the working model, allowed to cure initially by way of the chemical additives, and final cure established by curing all of the brackets in a curing unit. A light-cured adhesive can also be used, and this resin can be manually placed onto the bracket base as well and then cured with a handheld curing light or light cure unit (Fig 25A and B). Also, a thermally cured adhesive is available, is placed on the brackets in the usual manner, and then cured with a toaster oven at 325°F for 15 minutes (Fig 26).

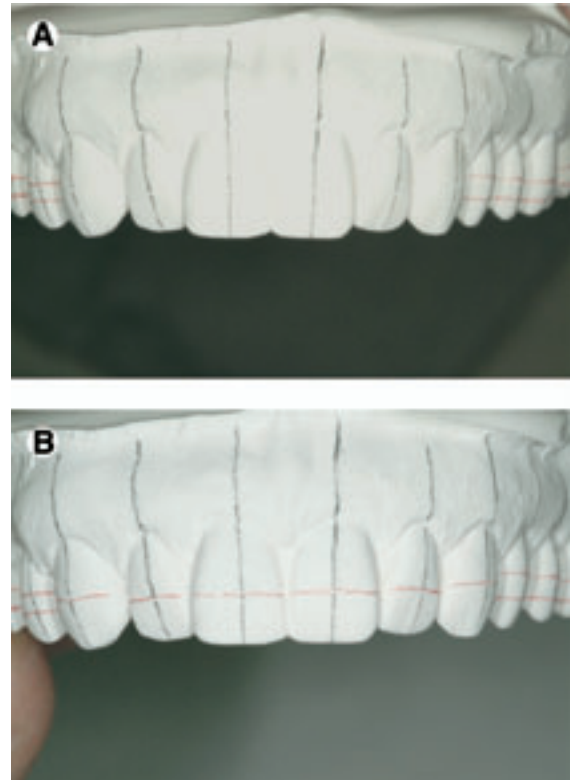


Figure 16. (A and B) Reference marks are placed, and then the slot lines for the anterior teeth are completed. (Color version of figure is available online.)

All of the previously mentioned methods for custom base fabrication are perfectly suitable, but have the disadvantage of requiring significantly more laboratory time for preparation. Currently, this author's preferred method in-

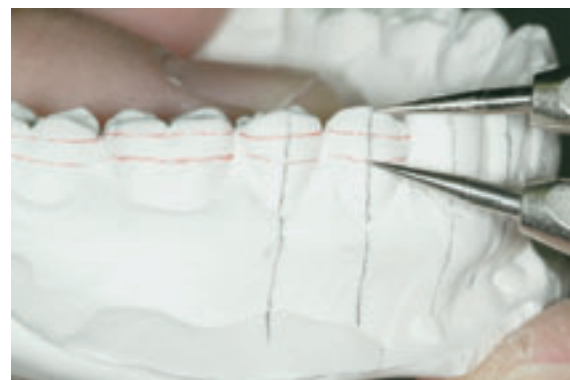

Figure 17. Measurement from the slot line to the tip of the lower first bicuspid. (Color version of figure is available online.)

volves use of brackets that are precoated with a light cured adhesive on the bases. After fabrication of the working models with the customized prescription, the models are coated with two light coats of a separating medium, which is diluted in a 1:3 ratio and allowed to dry thoroughly (Fig 27A and B). The brackets (Fig 28) are placed onto the models using the vertical and horizontal lines for reference. The preferred method is to place both central incisor brackets, then both lateral incisor brackets, and then the canine brackets moving to the posterior and continuing this pattern (Fig 29A-F). The brackets are seated against the models and checked against the lines using a bracket-positioning instrument. Once all of the brackets have been placed, an explorer is used to remove the excess composite (Fig 30). The final step in this bracket-positioning process is the most critical. A millimetric probe is used to measure the distance from the incisal edge of the tooth to the incisal edge of the bracket on all of the anterior teeth. It is necessary for the corresponding anterior teeth to be the same. In this example case, it is 2.5 mm for the centrals, 2 mm for the laterals, and 3 mm for the canines. It must be emphasized that it is not the magnitude of the measurement that is important in this last step, but it is very important for the measurements for the centrals to be identical, the measurements for the laterals to be identical, and finally, for the measurements for the canines to be identical (Fig 31A-F).

This procedure is repeated in the lower arch, beginning with the central incisors (Fig 32A and B) and proceeding to the posterior. When




Figure 18. The measurement is less than 4.0 mm. (Color version of figure is available online.)

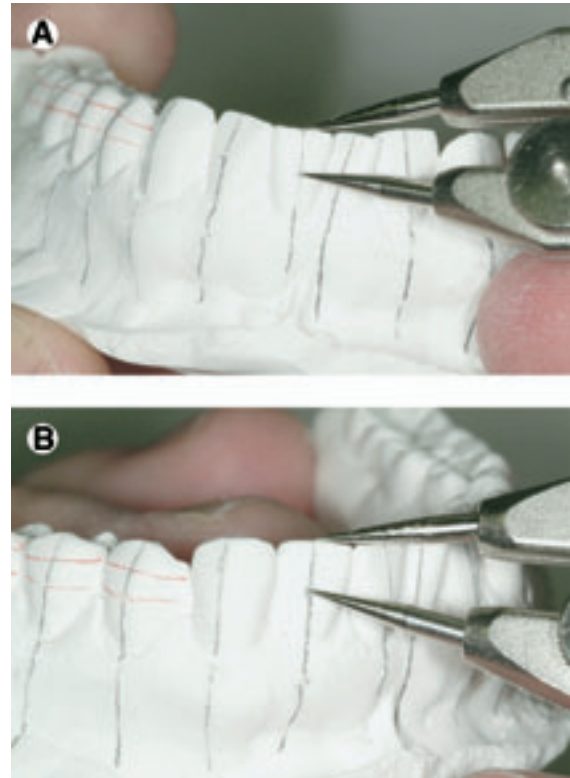


Figure 19. (A and B) Transfer this measurement to the central and lateral incisors. (Color version of figure is available online.)

all of the brackets have been seated on the working models, they are checked with the millimetric probe. The central and lateral incisors should all have the same measurement, and the canine measurement should correspond as well (Fig 33A-G). At this time, the brackets are ready to be



Figure 20. Increase the measurement by 0.5 mm for the mandibular canine. (Color version of figure is available online.)

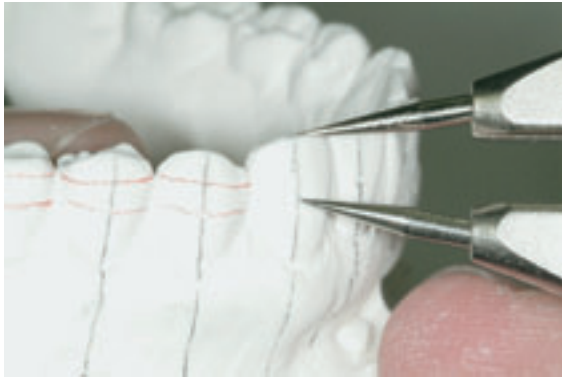

Figure 21. Transfer this measurement to the canine. (Color version of figure is available online.)

cured in a light-curing unit. In this author's office, the laboratory technician places all of the lines and seats the brackets on the models. The models are placed in a light-tight drawer, and the orthodontist then checks them at a convenient time using the millimetric probe for final bracket position confirmation.

Modifications to the Basic Prescription

When treating adult patients, it is not uncommon for one or more of the anterior teeth to be

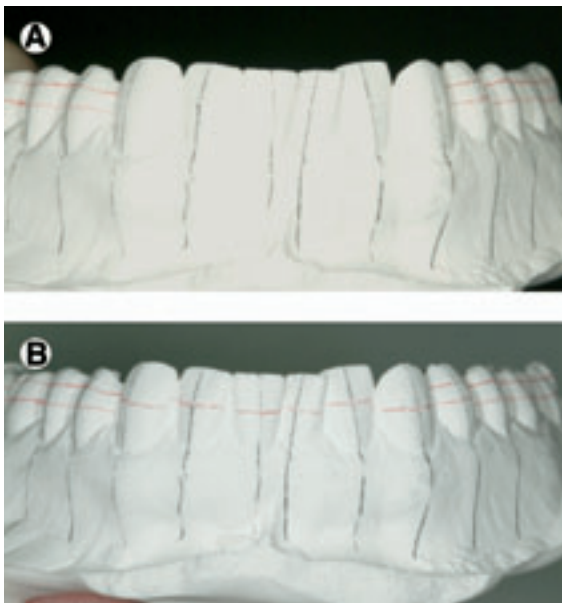


Figure 22. (A and B) Reference marks are placed, and then the slot lines for the anterior teeth are completed. (Color version of figure is available online.)

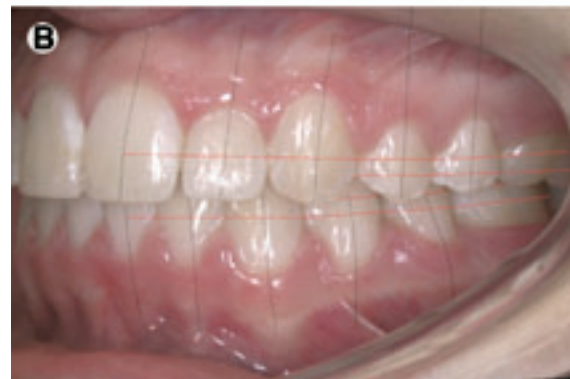
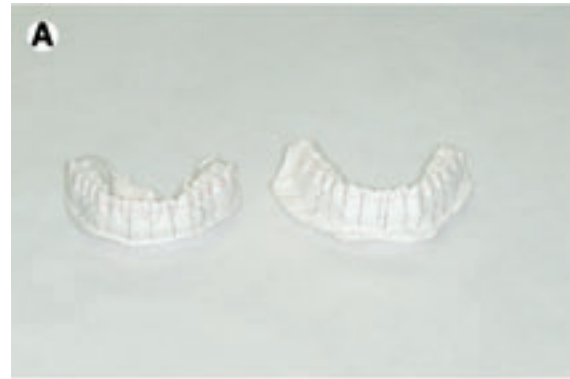
Figure 23. (A and B) Completed maxillary and mandibular working models with a customized prescription for bracket placement. Graphical representation of lines on completed case. (Color version of figure is available online.)

worn or broken down to the extent that restoration is necessary. The restoration can be completed at the end of orthodontic treatment, but may be compromised in its final form if the tooth is not placed in an ideal location at the end of treatment. It is therefore important when positioning brackets in these cases to position the brackets with reference to gingival margin architecture rather than to the incisal edges. In these cases it may be desirable to measure down from the gingival margin to the edge of the bracket to ensure that the gingival margins are in proper form at the end of treatment rather than having the incisal edges lined up. In cases where there is significant tooth wear, this may result in the brackets being placed on or near the incisal edge. It may be difficult to accept that these brackets are positioned appropriately; however, doing so will allow for final restorations that provide for better esthetics, as well as pro-

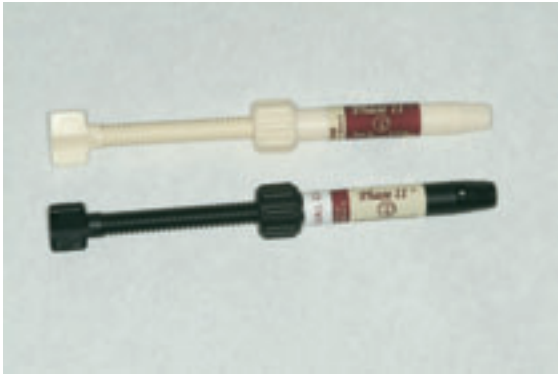

Figure 24. Dual cure resin, which can be used for custom base. (Color version of figure is available online.)



Figure 26. Thermally cured resins can also be used to create custom bases and are cured in a toaster oven at 325°F for 15 minutes. (Color version of figure is available online.)

vide for appropriate gingival margin form (Fig 34A-D).

Extraction cases present a unique challenge when considering marginal ridge alignment. This is especially true when second bicuspid are removed because this places the lower first mo-

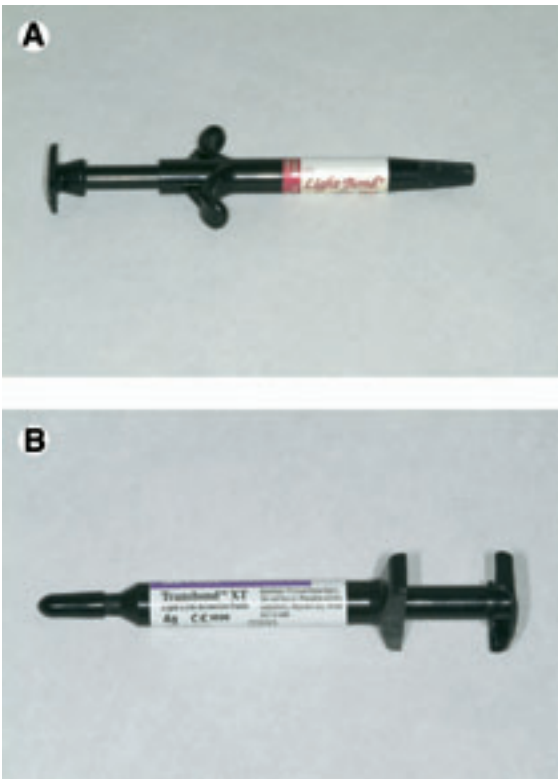


Figure 25. (A and B) Various forms of light-cured composites can be used for custom bases. (Color version of figure is available online.)



Figure 27. (A and B) One-to-three ratio of separating medium to water applied to the working models in two light coats. (Color version of figure is available online.)



Figure 28. Brackets used with adhesive coated on the bases from the manufacturer. (Color version of figure is available online.)

lar marginal ridge against a lower first bicuspid, which quite frequently resembles a canine in form and does not have a distinct marginal ridge. In these cases, it is recommended that the lower first bicuspid bracket be placed 0.5 mm to 1 mm more gingivally. In addition, in extraction cases, the brackets can be oriented with their long axis lines away from the extraction site to ensure root uprighting and parallelism during space closure.

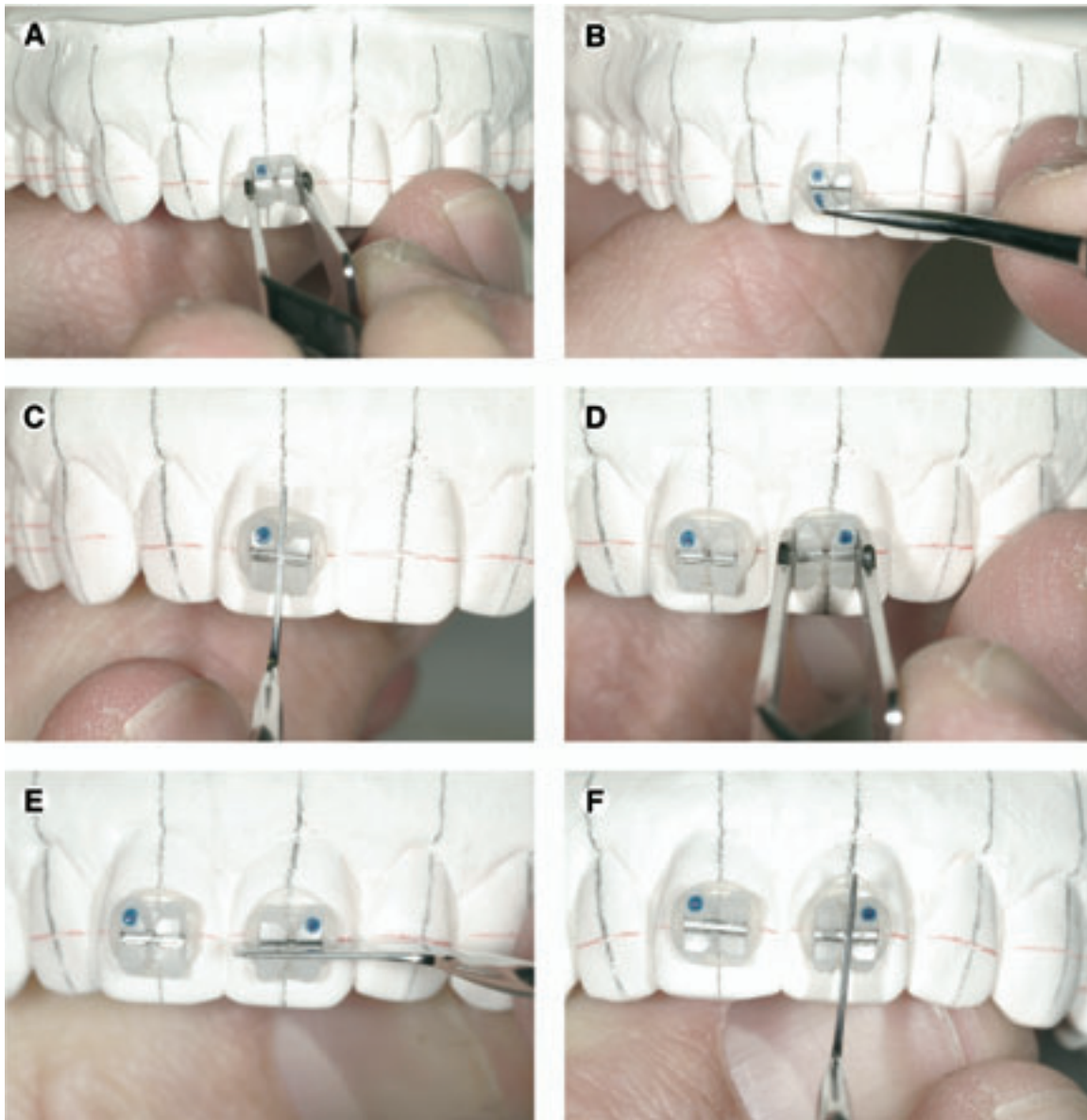


Figure 29. (A-F) Brackets are placed in pairs, beginning with the central incisors and then moving toward the posterior. (Color version of figure is available online.)

After the bracket positions are confirmed, the brackets are cured in a Triad 2000® (Dentsply International, York, PA) light-curing unit for 6 minutes (Fig 35). To prevent the bonding material from flowing into the slots and under the tie wings, and also to act as a carrier for the transfer trays, the recommendation is to place Unitek® cement guards (Unitek, Monrovia CA) on all of the brackets (Fig 36). These guards are placed by teasing them onto the brackets, and care must be exercised to prevent pulling the bracket off of the model. It has been found that using these guards has greatly enhanced the ability to remove the transfer trays and has decreased debonding of brackets during this step.

The next procedure is a critical step in the process. It involves construction of the transfer trays used to bond the brackets into place. There are differing opinions among the advocates of indirect bonding as to what material is best suited for transfer tray construction. The author has tried all possible techniques and materials for this step including single light cure and dual cure clear silicones, two-part liquid/putty silicones, single and dual clear Biostar® trays (Great Lakes Orthodontics, Tonawanda, NY), and two-part heavy viscosity silicone putties. Despite an ongoing effort to find a better method, this author has always returned to the two-part heavy viscosity putty. Initially it was considered that having a clear tray would be a benefit in using light-cured materials and also would make it easier to visualize seating of the transfer trays. However, use of this method has indicated that there were really very few benefits to a clear tray. Chemically cured composites have very similar components to those that are light cured and therefore have the same clinical working characteristics. Light-cured resins actually take much longer to cure at the chairside and thus detract from the efficiency of indirect bonding. Also, the benefit of visualization through a clear tray is lost as soon as the trays are seated because of the patient's lips and cheeks and because of the hands of the operator. The material of choice remains Exaflex® Very High Viscosity Putty (Exaflex, GC America, Alsip, IL).

This material is prepared by thoroughly mixing equal portions of the two putty components to form a thick rope (Fig 37A-C). The putty is

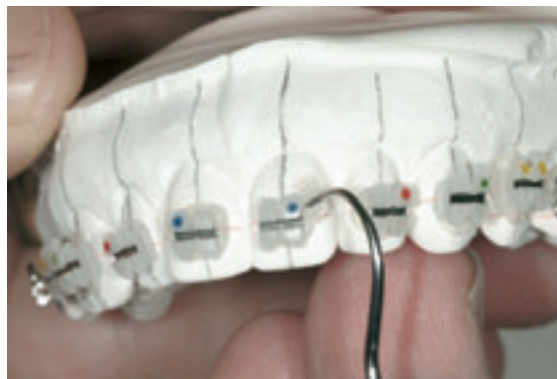

Figure 30. Explorer used to remove excess composite from around the bracket bases. (Color version of figure is available online.)

then adapted to the model to cover the brackets and is extended over occlusal and onto the lingual (Fig 38A and B). It is important to maintain an adequate thickness of material to provide rigidity for positive seating of the tray.

Once the trays have hardened, place the models into a bowl of warm water and allow them to soak for 30 minutes (Fig 39). Alternatively, the models can be placed into a pressure pot with warm water for 10 minutes (Fig 40). The trays are then removed from the models and placed upright into the Triad 2000® (Triad 2000, Dentsply International, York, PA) for an additional 1 minute to ensure complete curing of the custom bases (Fig 41). The trays are then cleaned with distilled water and a clean toothbrush (Fig 42).

The trays are trimmed to the level of the bracket on the facial and buccal aspects, and then trimmed to allow for the tray to extend over the lingual on the anterior surfaces and also over the lingual cusps by about 2 mm on the lingual of the posterior teeth (Fig 43). The trays are then cut interproximally from the lingual to the level of the contacts. The latter has been found to be a major improvement in the tray design and to greatly facilitate removal of the trays. These interproximal slices increase the flexibility in a lingual-to-facial direction, but do not hinder the necessary stiffness in the opposite direction (Fig 44A-C). The custom bases are then micro-etched with 50- μ m aluminum oxide (Fig 45), rinsed with distilled water, and dried with forced air.

Clinical Procedure

Before isolation of the teeth, they should be cleaned with a fluoride-free pumice paste. The Nola Dry Field System® (Nola Specialties, Hilton Head, SC) has been found to be the best for isolation in full arch indirect bonding (Fig 46). The teeth are etched with a 37% phosphoric acid solution or gel for 30 seconds per arch, then rinsed and thoroughly dried (Fig 47). On porcelain surfaces, it will be necessary to micro-etch the porce-

lain and then use a hydrofluoric acid porcelain etchant to prepare the surface (Fig 48). A moisture-insensitive primer may also be used on the teeth, if necessary. Self-etching primers have also been tested in indirect bonding, but have been found to generally have fewer advantages when bonding full arches.

Once the teeth are isolated, etched and dried, a silane coupling agent is placed on porcelain surfaces (Fig 49A and B). Sondhi Rapid Set Indirect

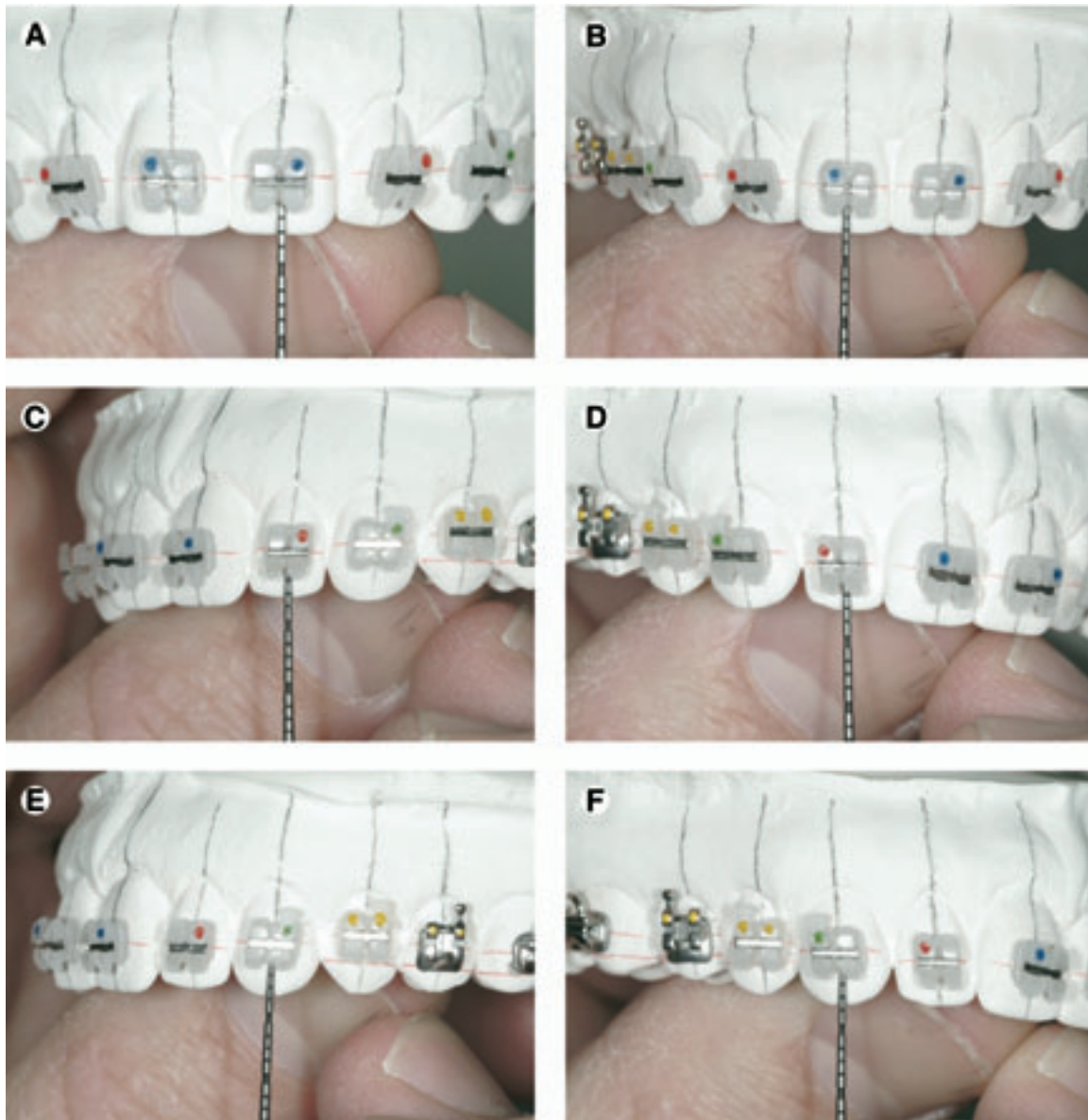


Figure 31. (A-F) A millimetric probe is used to verify bracket placement by comparing contralateral teeth with each other. (Color version of figure is available online.)

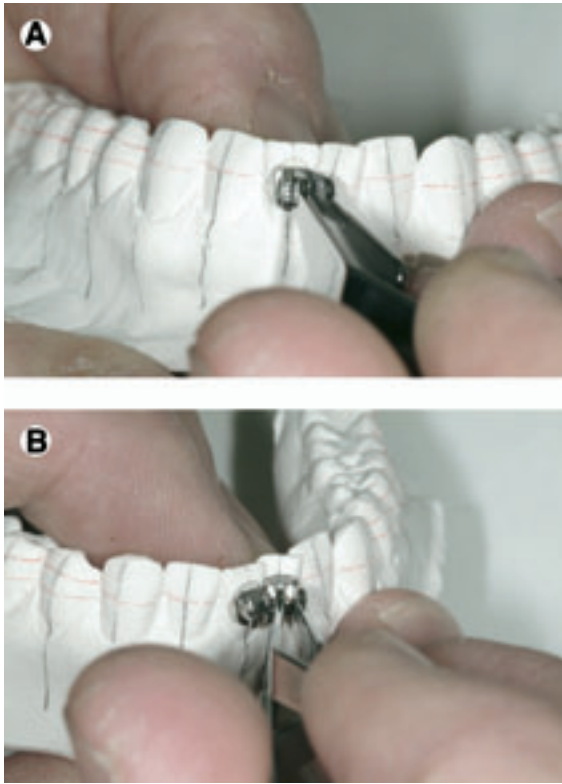


Figure 32. (A and B) The procedure is duplicated in the lower arch, beginning with the central incisors and moving toward the posterior. (Color version of figure is available online.)

Bonding Adhesive® (3M Unitek), or a similar fast-setting resin such as Custom I.Q.® (Reliance Orthodontic Products, Inc., Itasca, IL), is placed with one component in a thin layer on the teeth (Fig 50A-C) and the other component on the bracket bases in the transfer trays (Fig 51). The lower tray is seated from the 5 o'clock position using light finger pressure and held in place for 30 seconds (Fig 52). The upper tray is seated from the 12 o'clock position and held in place for 30 seconds (Fig 53). Both arches are allowed to cure for an additional 2 minutes (Fig 54A and B).

The trays are removed by placing a scaler under the distolingual edge of the tray and peeling from the lingual over the occlusal. The tray will come off easily and will come off in pieces (Fig 55A-D). Using the curette, the cement guards are removed as well as any remaining pieces of transfer tray material (Fig 56). Any remaining adhesive material is also removed with the scaler, paying particular attention to any adhesive that may have been squeezed onto the lingual of the incisors, interproximally, or the distal aspect of the second molar teeth (Fig 57A-C). Initial arch wires can now be inserted and the patient given any necessary care instructions (Fig 58).

Discussion

A unique method for bracket placement that uses vertical and horizontal reference lines placed on working models has been presented. These lines create a visual template for bracket placement and are unique for every patient. The lines are based on the concept of coupling defined treatment objectives and excellence in esthetics with the functional requirements of level marginal ridges and canine and incisor guidance. The use of this technique offers significant rewards in terms of quality of care and efficiency of treatment. It is quick, accurate, and reliable. In fact, it is not uncommon to be able to complete a full upper second molar to second molar bonding in 15 minutes or less. Overall this method enhances patient comfort by minimizing the number of appointments involved in appliance placement and also by minimizing patient chair time. Staff use is maximized and clinician time is used most efficiently. Efficiency of time in motion and operator ergonomics is enhanced.¹⁰ Appointment scheduling also becomes precise, orderly, and predictable. The simplicity, accuracy, and methodical nature of this technique will make the office run more efficiently and will generate a more pleasant and satisfying work environment.

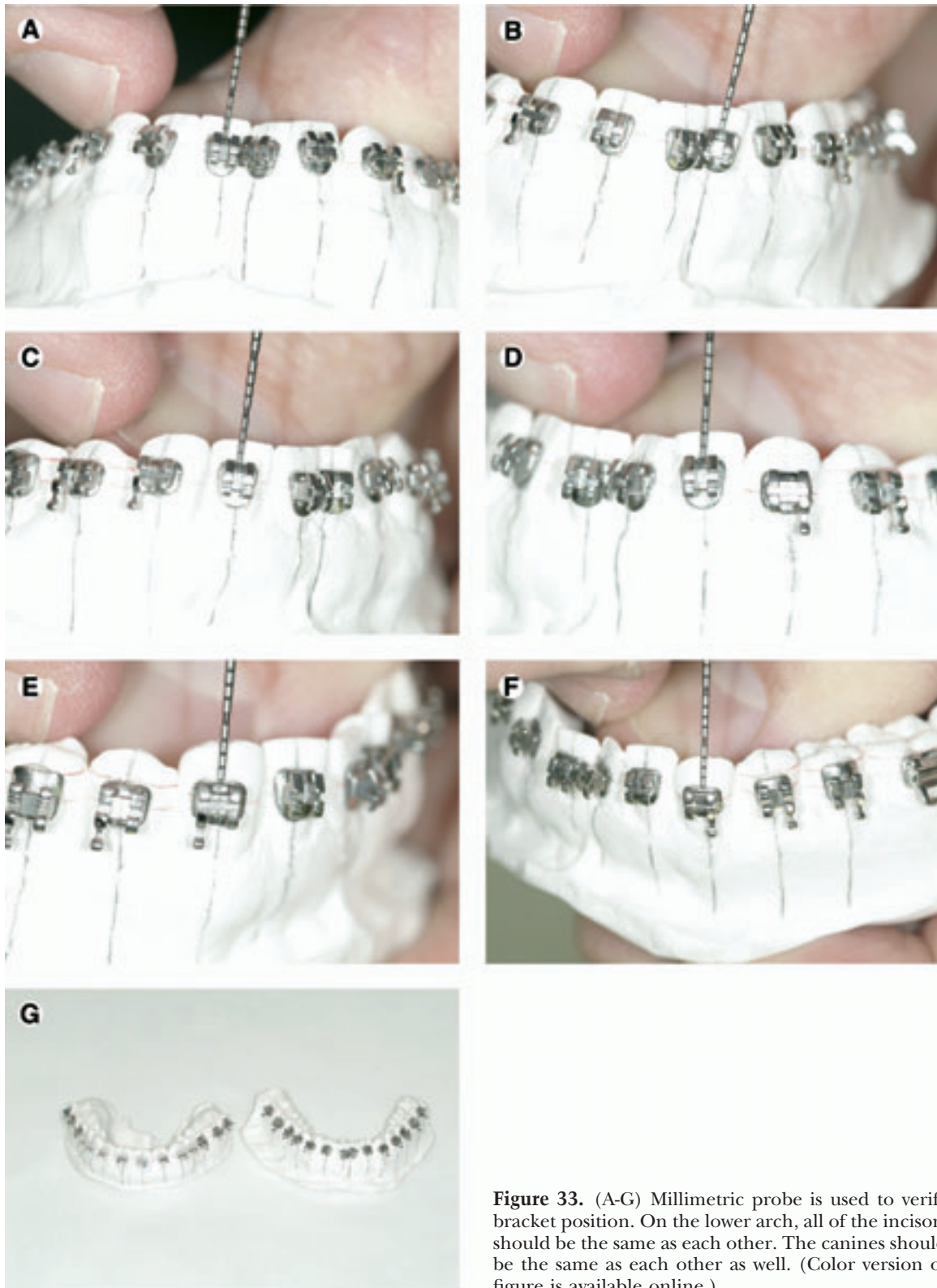


Figure 33. (A-G) Millimetric probe is used to verify bracket position. On the lower arch, all of the incisors should be the same as each other. The canines should be the same as each other as well. (Color version of figure is available online.)

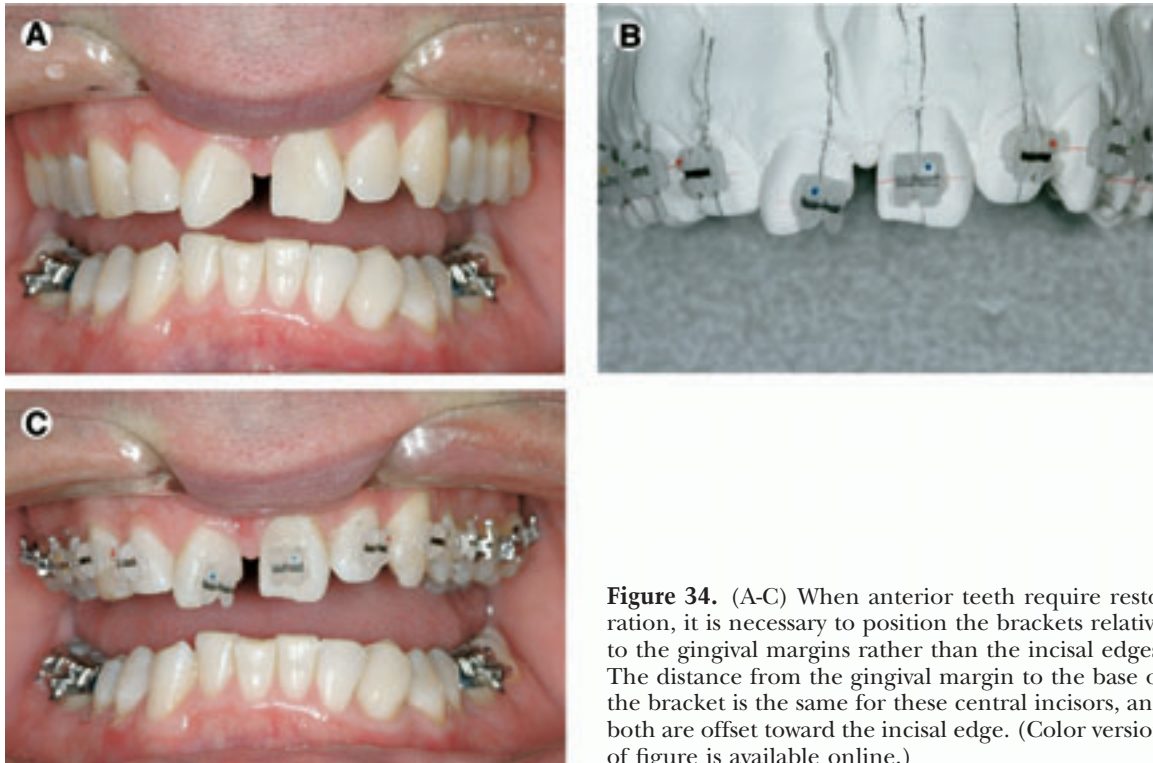


Figure 34. (A-C) When anterior teeth require restoration, it is necessary to position the brackets relative to the gingival margins rather than the incisal edges. The distance from the gingival margin to the base of the bracket is the same for these central incisors, and both are offset toward the incisal edge. (Color version of figure is available online.)




Figure 35. Models placed in a light-curing chamber for 6 minutes. (Color version of figure is available online.)

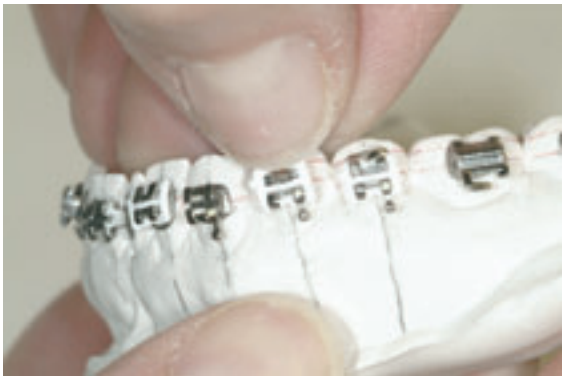

Figure 36. Cement guards placed on the brackets. (Color version of figure is available online.)

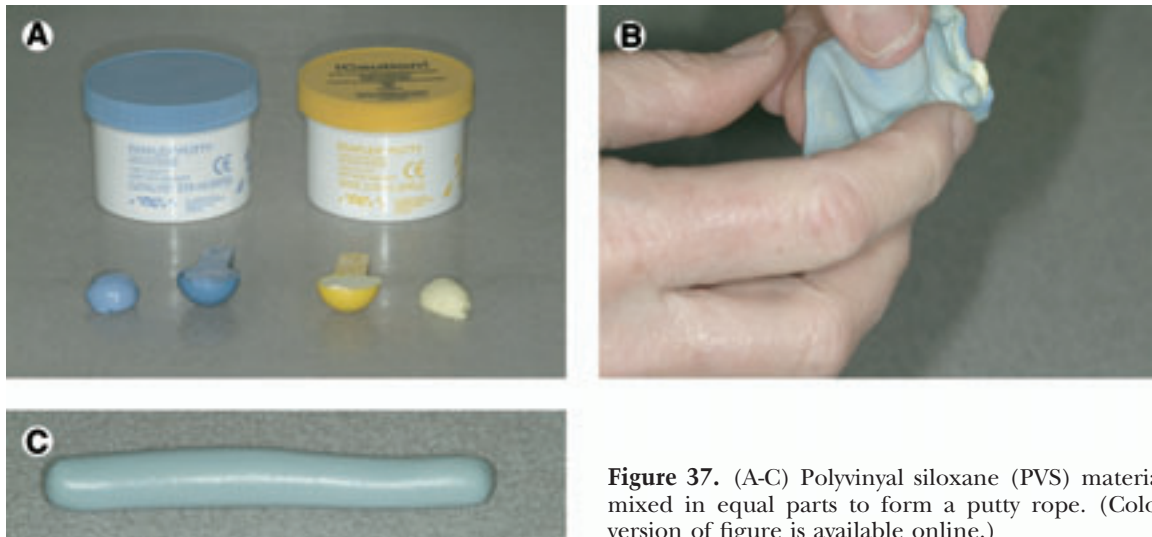


Figure 37. (A-C) Polyvinyl siloxane (PVS) material mixed in equal parts to form a putty rope. (Color version of figure is available online.)

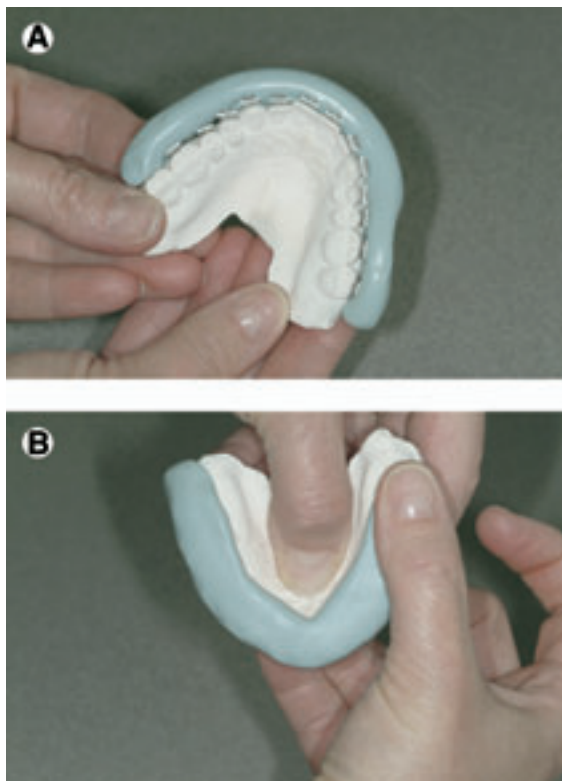


Figure 38. (A and B) PVS material adapted to the brackets and models. (Color version of figure is available online.)

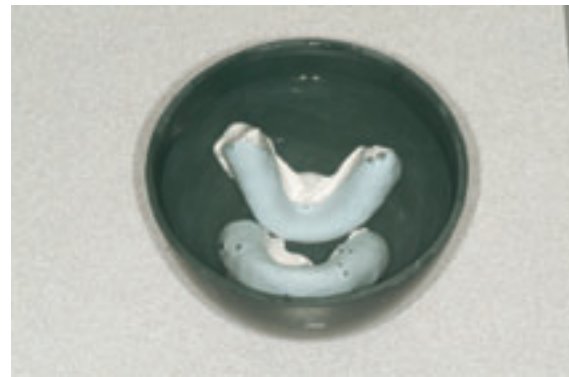

Figure 39. Models allowed to soak for 30 minutes. (Color version of figure is available online.)



Figure 40. Models placed in a pressure pot for 10 minutes. (Color version of figure is available online.)



Figure 41. Transfer trays are inverted and placed in the curing unit for an additional 1 minute. (Color version of figure is available online.)



Figure 42. Trays are cleaned with distilled water and a clean toothbrush. (Color version of figure is available online.)

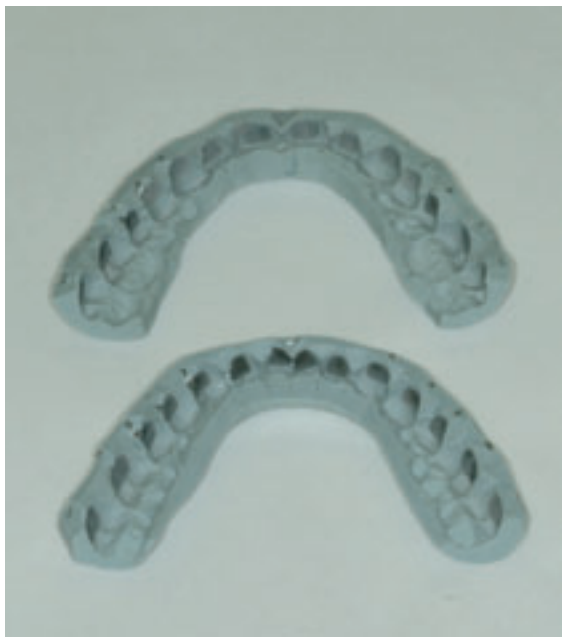

Figure 43. Final trays trimmed. (Color version of figure is available online.)



Figure 44. (A-C) Interproximal slices are made in the trays. This increases the flexibility in a lingual to facial direction, but does not hinder the necessary stiffness in the opposite direction. (Color version of figure is available online.)



Figure 45. Bracket bases are lightly micro-etched with 50 æm of aluminum oxide. (Color version of figure is available online.)

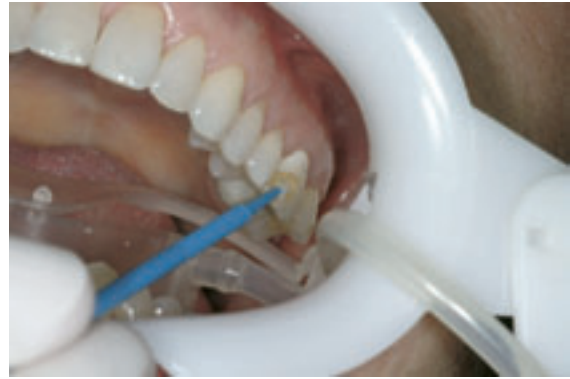

Figure 48. Porcelain surfaces are etched with 9.5% hydrofluoric acid etchant. (Color version of figure is available online.)

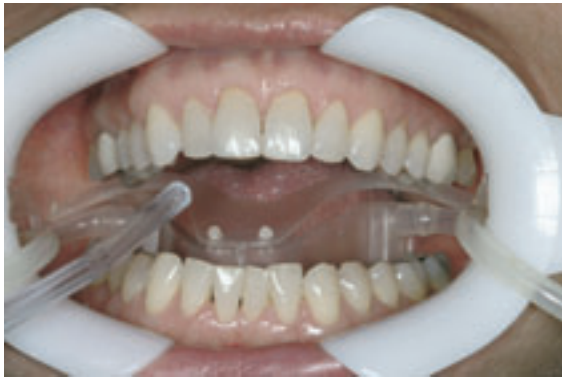

Figure 46. The dentition is isolated with a Nola Dry Field System®. (Color version of figure is available online.)

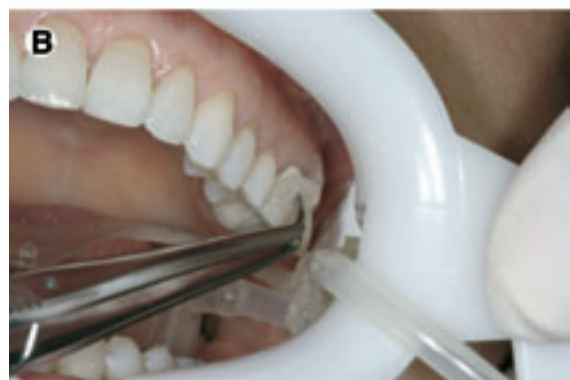

Figure 49. (A and B) Porcelain surfaces conditioned with a silane coupling agent. (Color version of figure is available online.)

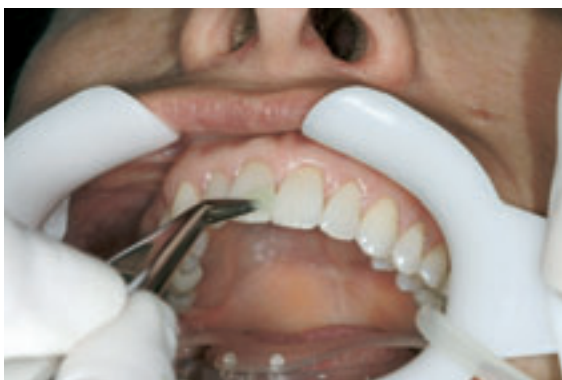

Figure 47. The teeth are etched with a 37% phosphoric acid etchant. (Color version of figure is available online.)

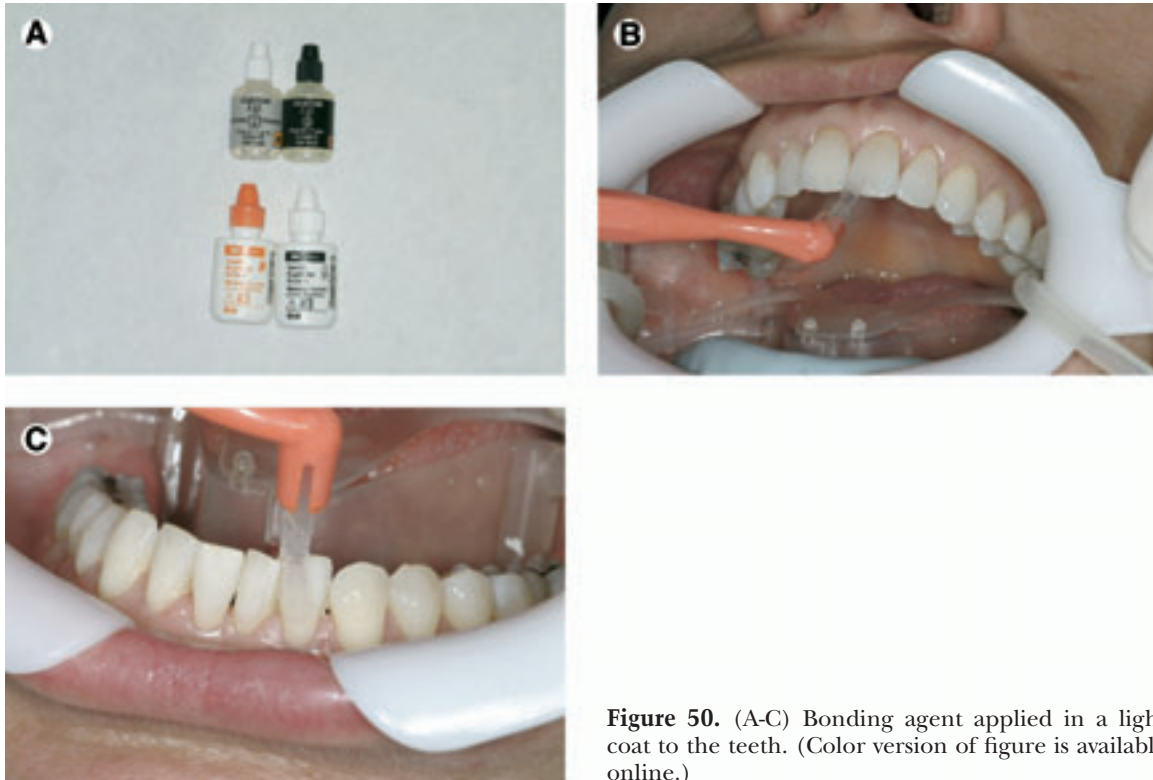


Figure 50. (A-C) Bonding agent applied in a light coat to the teeth. (Color version of figure is available online.)

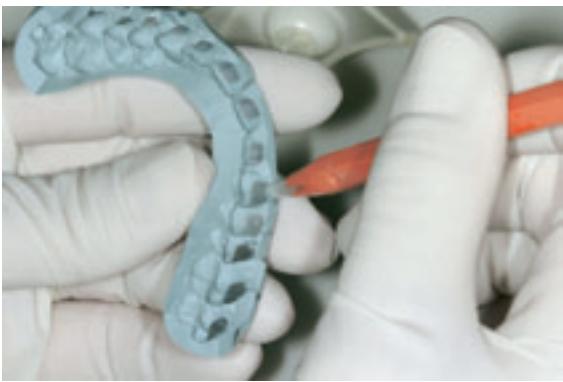

Figure 51. Bonding agent applied in a light coat to the custom resin base. (Color version of figure is available online.)



Figure 52. The lower tray is seated from the 5 o'clock position and allowed to cure. (Color version of figure is available online.)

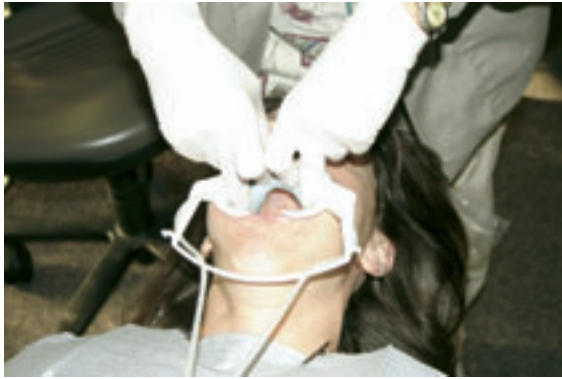

Figure 53. The upper tray is seated from the 12 o'clock position and allowed to cure. (Color version of figure is available online.)

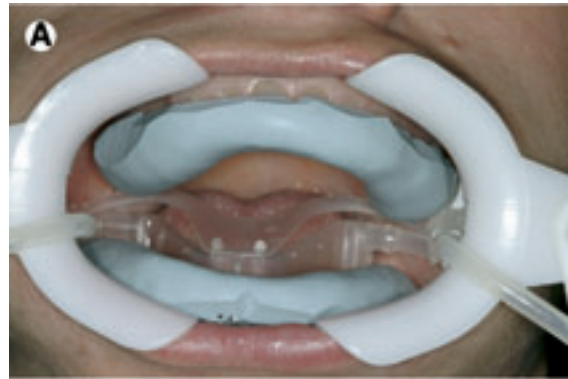


Figure 54. (A and B) The trays are allowed to cure undisturbed for an additional 2 minutes. (Color version of figure is available online.)

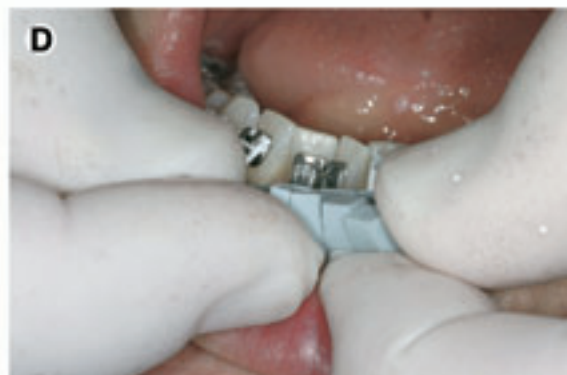
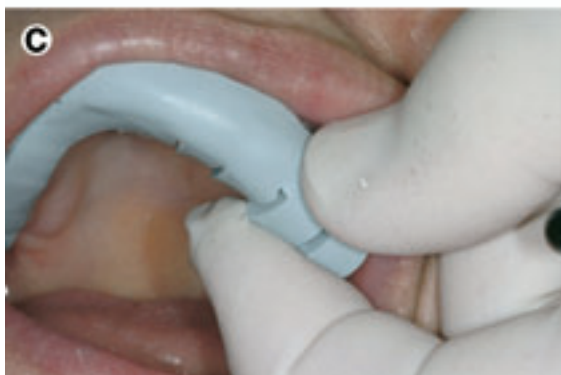
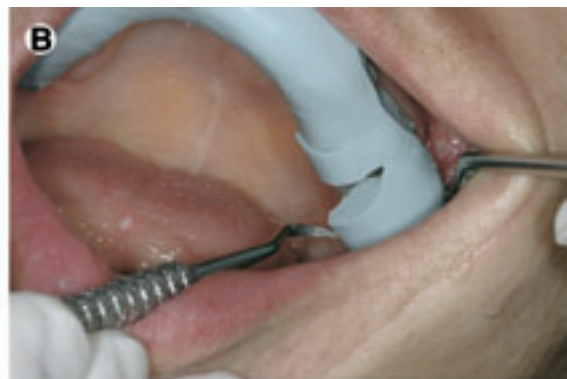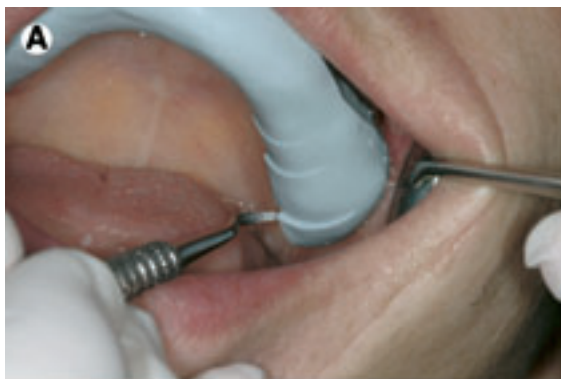Figure 55. (A-C) The transfer trays are removed, beginning from the distolingual of the second molars and finishing in the anterior. The trays will remove easily and will come off in pieces. (Color version of figure is available online.)

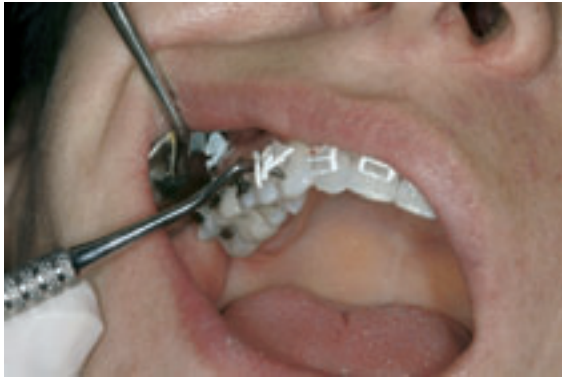

Figure 56. The cement guards and remaining tray material is removed. (Color version of figure is available online.)

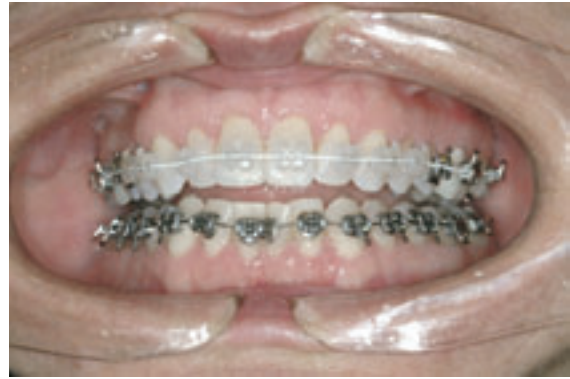

Figure 58. The archwires are placed immediately and home care instructions are given. (Color version of figure is available online.)

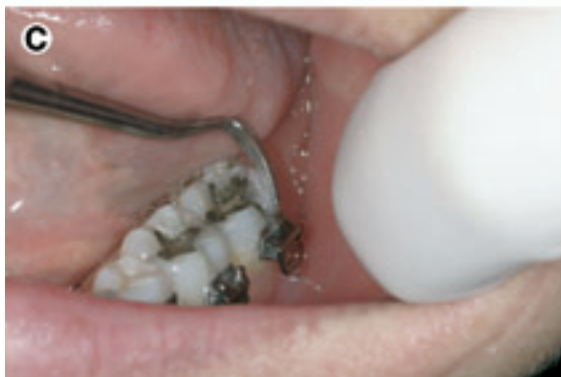
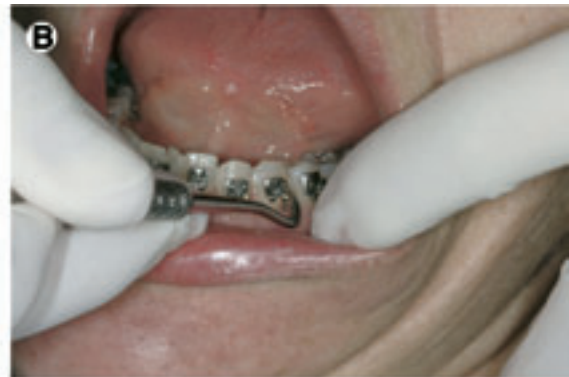
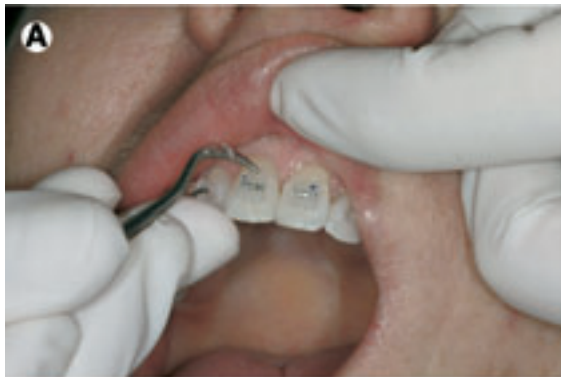Figure 57. (A-C) The remaining bonding agent is removed, paying particular attention to the interproximal areas and distal to the second molars. (Color version of figure is available online.)

References

1. Casco JS, Vaden JL, Kokich VC, et al: Objective grading system for dental casts and panoramic radiographs. *Am J Orthod Dentofacial Orthop* 114:589-599, 1998
2. Kalange JT: Ideal appliance placement with APC brackets and indirect bonding. *J Clin Orthod* 33:516-526, 1999
3. Andrews LF: *Straightwire: The Concept and Appliance*. San Diego, L.A. Wells, 1989
4. Roth RH: Functional occlusion for the orthodontist. *J Clin Orthod* 1:32-51, 1981
5. Roth RH: Functional occlusion for the orthodontist, Part III. *J Clin Orthod* 3:174-198, 1981
6. McLaughlin RP, Bennett JC, Trevisi HJ: Bracket positioning and case set-up, in *Systematized Orthodontic Treatment Mechanics*. Edinburgh, Mosby, 2001, pp 55-69
7. Kokich VG: Anterior dental esthetics: an orthodontic perspective, I: crown length. *J Esth Dent* 5:19-23, 1993
8. Kokich VG: Anterior dental esthetics: an orthodontic perspective, II: vertical relationships. *J Esth Dent* 5:174-178, 1993
9. Kokich VG: Anterior dental esthetics: an orthodontic perspective, III: mesiolateral relationships. *J Esth Dent* 5:200-207, 1993
10. Kalange JT: Indirect bonding: a comprehensive review of the advantages. *World J Orthod* 5:301-307, 2004